UpToDate®
Official reprint from UpToDate®
www.uptodate.com © 2026 UpToDate, Inc. and/or its affiliates. All Rights Reserved.

Overview of the acute management of tachyarrhythmias in adults

AUTHOR: Jordan M Prutkin, MD, MHA, MHS
SECTION EDITORS: James Hoekstra, MD, Hugh Calkins, MD, Brian Olshansky, MD
DEPUTY EDITOR: Naomi F Botkin, MD

All topics are updated as new evidence becomes available and our peer review process is complete.

Literature review current through: **Jan 2026.**
This topic last updated: **Feb 04, 2026.**

INTRODUCTION

Tachyarrhythmias, defined as heart rhythms with a ventricular rate ≥100 beats per minute, can be symptomatic and require inpatient or outpatient evaluation and management. Tachyarrhythmias may cause hemodynamic collapse and be associated with shock, hypotension, heart failure, dyspnea, chest pain, myocardial infarction, palpitations, decreased level of consciousness, and death; alternatively, they may simply be benign and asymptomatic. An overview of tachyarrhythmia management is presented here. Complete reviews of each individual arrhythmia are presented separately.

In the discussion below, sinus tachycardia is classified as a tachyarrhythmia although some of our experts disagree with this designation.

INITIAL DIAGNOSTIC AND TREATMENT DECISIONS

In patients who present with a symptomatic tachyarrhythmia, the symptoms should be categorized and the vital signs assessed. The symptom severity can range from cardiac arrest to syncope to palpitations alone, and the urgency to intervene is related to the clinical presentation. After the initial assessment of the patient's overall status is performed, rhythm monitoring is required, and if possible, a 12-lead ECG must be obtained. The information from this initial assessment is crucial for subsequent management.

Is the patient clinically (or hemodynamically) unstable? — The most important clinical determination in a patient presenting with a tachyarrhythmia is whether or not the patient is experiencing signs and symptoms related to the rapid heart rate. These can include hypotension, shortness of breath, chest pain suggestive of coronary ischemia, shock, and/or decreased level of consciousness.

In rare instances, tachyarrhythmias can persist and cause tachyarrhythmia-induced cardiomyopathy with subsequent heart failure, even if only initially mildly symptomatic, so long-term treatment to prevent persistent frequent and prolonged episodes is a goal even if few symptoms are present.

Determining whether a patient's symptoms are related to the tachycardia depends upon several factors, including age and the presence of underlying cardiac disease.

- **Hemodynamically unstable and not sinus rhythm** – If a patient is hemodynamically unstable and tachycardic, an attempt should be made to distinguish between a tachyarrhythmia and sinus tachycardia. If a tachyarrhythmia is present, **urgent conversion** is recommended (algorithm 1) [1]. (See "Basic principles and technique of external electrical cardioversion and defibrillation" and "Cardioversion and defibrillation for specific arrhythmias".)

Cardioversion should not be performed for sinus tachycardia because the hemodynamic instability in that case is due to an underlying noncardiac issue, not the tachycardia itself. Cardioversion should terminate the tachyarrhythmia, returning the patient to normal sinus rhythm or a different underlying slower rhythm (eg, permanent atrial fibrillation). If the patient is alert and awake and it is feasible, cardioversion should be performed with anesthesia or, at least, deep sedation.

- **Hemodynamically stable** – If the patient is not experiencing hemodynamic instability, a nonemergent approach to the diagnosis of the patient's rhythm can be undertaken [2-5]. Close examination of the 12-lead ECG, comparison to prior ECGs, and continuous rhythm monitoring can facilitate correct identification of the arrhythmia in most cases. (See 'Is the QRS complex narrow or wide? Regular or irregular?' below and "Wide QRS complex tachycardias: Approach to the diagnosis", section on 'Evaluation of the electrocardiogram' and "Narrow QRS complex tachycardias: Clinical manifestations and evaluation of the electrocardiogram", section on 'Irregular tachycardias'.)

Is the QRS complex narrow or wide? Regular or irregular? — Treatment of any tachyarrhythmia depends on a variety of clinical factors. However, most treatment decisions are made based on the width, morphology, and regularity of the QRS complex as well as the rate of the tachycardia (algorithm 2). It is well established that a persistent SVT with rates over 120 to 130 can lead to a rate-related cardiomyopathy over a several-week period of time. In most patients, the differentiation between narrow and wide QRS complex tachyarrhythmias requires only a surface ECG.

- Narrow QRS complex tachyarrhythmias have a QRS complex <120 milliseconds in duration
- Wide QRS complex tachyarrhythmias have a QRS complex ≥120 milliseconds in duration. The complexes may be uniform or may vary in morphology and width.



Algorithm for the initial ECG review and differential diagnosis of tachycardia

Algorithm 2 - larger image below

The various types of narrow and wide QRS complex tachyarrhythmias are discussed below. (See 'Narrow QRS complex tachyarrhythmias' below and 'Wide QRS complex tachyarrhythmias' below.)

NARROW QRS COMPLEX TACHYARRHYTHMIAS

Discussion of the treatment of narrow QRS complex tachycardias will be divided into those with a regular ventricular response and those with an irregular ventricular response. (See "Narrow QRS complex tachycardias: Clinical manifestations and evaluation of the electrocardiogram", section on 'Evaluation of the electrocardiogram'.)

Regular narrow QRS complex tachyarrhythmias — The regular narrow QRS complex tachycardias include (algorithm 2) [4]:

- Sinus tachycardia (see "Sinus tachycardia: Evaluation and management")
- Inappropriate sinus tachycardia (see "Sinus tachycardia: Evaluation and management", section on 'Inappropriate sinus tachycardia')
- Sinoatrial nodal reentrant tachycardia (SANRT) (see "Sinoatrial nodal reentrant tachycardia (SANRT)")
- Atrioventricular nodal reentrant tachycardia (AVNRT) (see "Atrioventricular nodal reentrant tachycardia")
- Atrioventricular reentrant (or reciprocating) tachycardia (AVRT), including permanent junctional reciprocating tachycardia (see "Atrioventricular reentrant tachycardia (AVRT) associated with an accessory pathway")
- Atrial tachycardia (AT) (see "Focal atrial tachycardia")
- Atrial flutter (see "Atrial flutter: Overview of diagnosis and management")

- Intraatrial reentrant tachycardia (IART) (see "Intraatrial reentrant tachycardia")
- Junctional ectopic tachycardia
- Nonparoxysmal junctional tachycardia

Because the vast majority of regular narrow QRS complex tachycardias are due to sinus tachycardia, AVNRT, AVRT, AT, and atrial flutter, these conditions will be presented here. Discussions regarding the treatment of the other less common types of regular narrow QRS complex tachycardias are presented separately. (See "Sinus tachycardia: Evaluation and management", section on 'Inappropriate sinus tachycardia' and "Sinoatrial nodal reentrant tachycardia (SANRT)", section on 'Treatment' and "Intraatrial reentrant tachycardia", section on 'Treatment' and "Treatment of arrhythmias associated with the Wolff-Parkinson-White syndrome".)

Distinguishing among the arrhythmias — In many cases, the evaluation of atrial activity on the electrocardiogram (ECG) leads to the correct diagnosis. If P waves cannot be identified, vagal maneuvers and intravenous adenosine may help clarify the nature of the arrhythmia. The use of the ECG, vagal maneuvers, and adenosine to identify narrow QRS complex arrhythmias is discussed elsewhere (algorithm 3). (See "Narrow QRS complex tachycardias: Clinical manifestations and evaluation of the electrocardiogram", section on 'Irregular tachycardias'.)

Common arrhythmias

Sinus tachycardia — The most common tachycardia is sinus tachycardia (waveform 1 and waveform 2) [6]. The presence of atrial tachycardia should alert the clinician that the patient may be seriously ill and a thorough evaluation is needed to detect the underlying cause of the sinus tachycardia. If it is certain that the patient's rhythm is sinus tachycardia and clinically significant cardiac symptoms are present, management should be focused on the underlying disorder and on treating any contributing cause of the rapid heart rate (eg, infection, pneumothorax, bleeding, myocardial infarction, coronary ischemia, pulmonary embolism, respiratory or cardiac failure, hypovolemia, anemia, hyperthyroidism, fever, pain, or anxiety). This may include volume replacement or diuresis, antibiotics, anti-pyretics, oxygen, pain control, or other treatments as appropriate. In patients with sinus tachycardia and certain forms of heart disease, such as coronary disease or aortic stenosis, treatment may need to be directed at the heart rate itself. Rarely, intravenous beta blocker is appropriate for acute management. (See "Sinus tachycardia: Evaluation and management" and "Acute myocardial infarction: Role of beta blocker therapy" and "Medical management of symptomatic aortic stenosis".)

Atrioventricular nodal reentrant tachycardia (AVNRT) — Patients with AVNRT (figure 1) associated with hemodynamic compromise or severe symptoms due to the tachycardia (eg, angina, hypotension, or heart failure) require rapid termination of the arrhythmia. (See "Atrioventricular nodal reentrant tachycardia", section on 'Initial management'.)

- For patients with AVNRT who are hemodynamically unstable related to their arrhythmia, we recommend immediate DC cardioversion. Consideration for using vagal maneuvers (Valsalva maneuver or carotid sinus massage) is also reasonable if it does not delay cardioversion. Hemodynamically unstable AVNRT is unusual. (See "Vagal maneuvers".)

- For patients with AVNRT associated with severe symptoms due to the tachycardia (eg, angina, hypotension, heart failure, or mental status changes) in whom intravenous access is available, we suggest an initial attempt at termination with adenosine (algorithm 4) rather than cardioversion. If adenosine cannot be administered or is ineffective, patients should undergo immediate DC cardioversion.



- For patients with AVNRT that is **not** associated with severe symptoms or hemodynamic collapse, including patients without symptoms, we suggest the following sequential approach to acute termination:
  - Vagal maneuvers (see "Vagal maneuvers")
  - IV adenosine (algorithm 4)
  - IV non-dihydropyridine calcium channel blocker or an IV beta blocker

Approach to adenosine dosing in stable adults with suspected supraventricular tachyarrhythmia

Algorithm 4 - larger image below

Atrioventricular reentrant tachycardia (AVRT) — Patients with AVRT, which is a reentrant arrhythmia that requires an accessory pathway, should have a prompt initial assessment of hemodynamic status. The management of AVRT depends on the stability of the patient and whether the mechanism of tachycardia is known or unknown. The approach to management of orthodromic AVRT (waveform 3), which most commonly presents with narrow QRS complexes, is discussed separately. (See "Treatment of arrhythmias associated with the Wolff-Parkinson-White syndrome", section on 'Orthodromic AVRT (regular, narrow QRS complex)'.)

Atrial tachycardia — Focal atrial tachycardias (ATs) are usually paroxysmal and self-limited, but they can be persistent and require treatment acutely (waveform 4). As noted, persistent atrial tachycardia with a heart rate over 120 to 130 can lead to a rate-related cardiomyopathy over a number of weeks. Thus, efforts to restore sinus rhythm are needed even if the patient is asymptomatic, although cardioversion is not required acutely in the absence of hemodynamic instability. (See "Focal atrial tachycardia", section on 'Acute treatment'.)

- For patients with AT who are hemodynamically unstable related to their arrhythmia, we recommend DC cardioversion. Instability due to AT is rare.

- For a hemodynamically stable patient with symptomatic AT, we suggest acute treatment with an oral or intravenous beta blocker (eg, metoprolol) or non-dihydropyridine calcium channel blocker (ie, diltiazem or verapamil). Such treatment may slow the ventricular response and/or terminate the arrhythmia. Intravenous amiodarone is an acceptable alternative that may be preferred in a patient with borderline hypotension as amiodarone may slow the rate or convert the rhythm back to normal sinus.

Atrial flutter — Atrial flutter (waveform 5) usually presents as a regular narrow complex tachycardia, though it occasionally may have an irregular ventricular response. Atrial flutter should always be considered high on the differential diagnosis when a patient presents with a regular narrow complex tachycardia with a ventricular response of approximately 150 beats per minute. As with atrial fibrillation, the early steps in the management of a patient with new onset atrial flutter involve an assessment of the need for cardioversion, ventricular rate slowing therapy, and antithrombotic therapy. Our initial approach to the management of patients with atrial flutter is the same as our approach for atrial fibrillation. However, atrial flutter is notoriously more difficult to rate control than atrial fibrillation. (See 'Atrial fibrillation' below.)

Irregular narrow QRS complex tachyarrhythmias — The irregular narrow QRS complex tachycardias include (algorithm 2):

- Atrial fibrillation (AF) (see "Atrial fibrillation: Overview of management")
- Atrial flutter with variable conduction (see "Atrial flutter: Overview of diagnosis and management")
- Focal atrial tachycardia with variable conduction (see "Focal atrial tachycardia")
- Multifocal atrial tachycardia (MAT) (see "Multifocal atrial tachycardia")
- Pulmonary vein tachycardia (irregular atrial tachycardia arising from a pulmonary vein)

Atrial fibrillation — Most patients with new onset (ie, first detected or diagnosed) AF with a rapid rate present with symptoms related to the arrhythmia (waveform 6). Except for embolization, the symptoms associated with new-onset AF are primarily due to a rapid and/or irregular ventricular response, along with loss of atrial

contraction. The early steps in the management of a patient with new-onset AF with rapid ventricular response involve an assessment of the need for cardioversion, ventricular rate slowing therapy, and antithrombotic therapy [5,7]. (See "Atrial fibrillation in adults: Rate control in patients without heart failure", section on 'Urgent therapy' and "Atrial fibrillation: Overview of management", section on 'Initial management of new-onset AF'.)

- Urgent or emergent cardioversion should be considered for patients with active ischemia, significant hypotension, severe heart failure, or the presence of a preexcitation syndrome associated with rapid conduction using the accessory pathway. (See 'Atrioventricular reentrant tachycardia (AVRT)' above and "Treatment of arrhythmias associated with the Wolff-Parkinson-White syndrome", section on 'Atrial fibrillation with preexcitation (irregular, wide QRS complex)'.)

- For all patients who do not require urgent or emergent cardioversion, we recommend rate control to improve symptoms and to reduce the risk of tachycardia-mediated cardiomyopathy. We believe a goal of less than 110 beats per minute is reasonable for an asymptomatic patient with a normal ejection fraction. Beta blockers and non-dihydropyridine calcium channel blockers are preferred as first-line agents in most patients, and digoxin should only rarely be used. Intravenous preparations are preferred to oral preparations when rapid control of rate is necessary.

- For patients with AF documented to be less than 48 hours in duration and in whom cardioversion is planned, the use of antithrombotic therapy precardioversion to reduce the risk of embolization can be considered.

- For patients with AF longer than 48 hours in duration (or of unknown duration), we recommend four weeks of therapeutic oral anticoagulation prior to cardioversion, as opposed to immediate cardioversion. Transesophageal echocardiography-based (TEE) screening for the presence of atrial thrombi is recommended if cardioversion is desired earlier than four weeks. Anticoagulation must be continued for a minimum of four weeks after cardioversion. Whether long-term anticoagulation is indicated depends on assessment of the patient's thromboembolic risk profile. (See "Atrial fibrillation in adults: Selection of candidates for long-term anticoagulation".)

Atrial flutter — As with atrial fibrillation, the early steps in the management of a patient with new onset atrial flutter involve an assessment of the need for cardioversion, ventricular rate slowing therapy, and antithrombotic therapy. Our initial approach to the management of patients with atrial flutter is the same as our approach for atrial fibrillation. (See 'Atrial fibrillation' above.)

Multifocal atrial tachycardia — Multifocal atrial tachycardia (MAT) is an arrhythmia with organized atrial activity yielding P waves with three or more different morphologies (waveform 7). MAT is commonly associated with significant underlying pulmonary or cardiac illness. (See "Multifocal atrial tachycardia", section on 'Treatment'.)

- Most episodes of MAT do not precipitate hemodynamic compromise or limiting symptoms. Thus, therapy in patients with MAT should be aimed at the inciting underlying disease.

- Patients with MAT and associated hypokalemia or hypomagnesemia should undergo electrolyte repletion prior to the initiation of additional medical therapy for MAT.

- Medical therapy for MAT is indicated only if MAT causes a sustained rapid ventricular response that causes or worsens myocardial ischemia, heart failure, peripheral perfusion, or oxygenation. Options for medical therapy for patients with symptomatic MAT requiring ventricular rate control include non-dihydropyridine calcium channel blockers and beta blockers. For patients without heart failure or bronchospasm, we suggest initial therapy with a beta blocker, usually metoprolol, before calcium channel blockers. Conversely, for patients with severe bronchospasm, we suggest initial therapy with a non-dihydropyridine calcium channel blocker, usually verapamil, rather than a beta blocker. Beta blockers may be used cautiously in patients with stable heart failure. Rate control therapy is typically unsuccessful, however, without treating the underlying disorder.

Pulmonary vein tachycardia — It is now well established that the most common trigger for atrial fibrillation is a rapid irregular atrial tachycardia arising from the pulmonary vein. In patients with AF, these bursts of atrial tachycardia trigger an AF episode (more than 30 seconds of atrial fibrillation). It is also now known that many patients with a "preatrial fibrillation" state have bursts of rapid irregular tachycardia with a duration of less than 30 seconds. This type of tachycardia is referred to as pulmonary vein tachycardia. Many patients previously diagnosed with MAT in fact have pulmonary vein tachycardia, especially in those without known pulmonary or cardiac disease. If a patient has pulmonary vein tachycardia, treatment with a beta blocker and/or an antiarrhythmic agent such as flecainide is advised. It is also recommended that these patients be followed closely as they are at high risk of developing atrial fibrillation over time. If atrial fibrillation develops, anticoagulation may be indicated.

WIDE QRS COMPLEX TACHYARRHYTHMIAS

Discussion of the treatment of wide QRS complex tachycardias, similar to narrow QRS complex tachycardias, can be divided into those with a regular or irregular ventricular rate.

Regular wide QRS complex tachyarrhythmias — An overview of the treatment of patients with regular, wide QRS complex tachycardias can be found below. A more detailed discussion is available elsewhere. (See "Wide QRS complex tachycardias: Approach to management".)

The regular wide QRS complex tachyarrhythmias include (algorithm 2):

- Monomorphic ventricular tachycardia (VT). (See "Sustained monomorphic ventricular tachycardia in patients with structural heart disease: Treatment and prognosis" and "Ventricular tachycardia in the absence of apparent structural heart disease".)
- Supraventricular tachycardia with aberrant conduction, underlying conduction delay, conduction over an accessory pathway (eg, AVNRT with right bundle branch block), or a paced ventricular response (waveform 8).
- Supraventricular tachycardia in a patient on certain antiarrhythmic medications or with significant electrolyte abnormalities.
- Antidromic atrioventricular reentrant tachycardia (AVRT) in a patient with Wolff-Parkinson-White (WPW) syndrome.

The most concerning potential cause of a wide QRS complex tachycardia is VT, and, in the majority of patients, the arrhythmia should be assumed to be VT until proven otherwise.

Immediate assessment of patient stability takes precedence over any further diagnostic evaluation. (See "Wide QRS complex tachycardias: Approach to management", section on 'Initial management'.)

- A patient who is unresponsive or pulseless should be treated according to standard advanced cardiac life support (ACLS) algorithms (algorithm 5).
- In a patient who is unstable but conscious, we recommend immediate synchronized cardioversion with appropriate sedation when possible.
- In a stable patient, a focused diagnostic evaluation may proceed to determine the etiology of the arrhythmia and guide specific therapy.

Ventricular tachycardia — The initial treatment of hemodynamically unstable VT (waveform 9 and waveform 10) is electrical cardioversion (algorithm 6) [8,9].

For most stable patients with VT, an intravenous (IV) antiarrhythmic medication (eg, amiodarone, procainamide, lidocaine) should be administered to achieve pharmacologic conversion. If the patient has an implantable cardioverter-defibrillator (ICD), antitachycardia pacing (ATP) is preferred if it can be performed quickly. Electrical cardioversion is generally reserved for patients in whom antiarrhythmic medication and/or ATP is ineffective because it requires IV sedation. (See "Sustained monomorphic ventricular tachycardia in patients with structural heart disease: Treatment and prognosis".)

Supraventricular tachycardia with aberrant conduction — A supraventricular tachycardia (SVT) may present with a wide QRS complex in the setting of aberrant conduction, underlying conduction delay, or conduction over an accessory pathway (not including AVRT).

In stable patients with a WCT that is **known or strongly suspected** to be an SVT, initial management is similar to that of an SVT with a narrow QRS complex. A continuous rhythm strip should be obtained during any intervention that is intended to slow or terminate the arrhythmia. (See 'Regular narrow QRS complex tachyarrhythmias' above.)

Supraventricular tachycardia with a pacemaker — Regular wide QRS complex tachycardias in patients with a pacemaker may be due to tracking of one of the typical supraventricular tachycardias (eg, sinus tachycardia, atrial flutter, etc) or may be due to pacemaker-mediated tachycardia (PMT, also referred to endless loop tachycardia [ELT]). Management of these patients is discussed separately. (See "Wide QRS complex tachycardias: Approach to management", section on 'Patients with a pacemaker' and "Unexpected rhythms with normally functioning dual-chamber pacing systems", section on 'Pacemaker-mediated tachycardia'.)

Antidromic AVRT — The approach to the acute management of stable patients with Wolff-Parkinson-White (WPW) syndrome who have acute symptomatic antidromic AVRT (regular and wide QRS complexes) is discussed separately. (See "Treatment of arrhythmias associated with the Wolff-Parkinson-White syndrome", section on 'Antidromic AVRT (regular, wide QRS complex)'.)

Irregular wide QRS complex tachyarrhythmias — The irregular wide QRS complex tachycardias include (algorithm 2):

- Polymorphic VT (eg, torsades de pointes, ischemia-mediated polymorphic VT, catecholaminergic polymorphic VT). (See "Acquired long QT syndrome: Definitions, pathophysiology, and causes" and "Catecholaminergic polymorphic ventricular tachycardia", section on 'Diagnostic testing and diagnosis' and "Ventricular arrhythmias during acute myocardial infarction", section on 'Polymorphic VT'.)
- Irregular narrow complex tachycardias with aberrant conduction, antegrade conduction over an accessory pathway (eg, preexcited AF), or underlying conduction delay (eg, AF with right bundle branch block).
- Ventricular fibrillation.

Polymorphic ventricular tachycardia — Polymorphic ventricular tachycardia (VT) (waveform 11) is defined as an unstable rhythm with a continuously varying QRS complex morphology in any recorded electrocardiographic (ECG) lead. Polymorphic VT is generally a rapid and hemodynamically unstable rhythm, and urgent defibrillation is usually necessary. In addition to immediate defibrillation, further therapy is intended to treat underlying disorders and to prevent recurrences. The specific approach depends upon whether or not the QT interval on the baseline ECG is prolonged. Polymorphic VT that occurs in the setting of QT prolongation in sinus rhythm is considered as a distinct arrhythmia, called torsades de pointes. Polymorphic VT that occurs in patients without QT prolongation is usually due to acute myocardial infarction but may be catecholaminergic polymorphic VT (CPVT) or Brugada syndrome. (See "Acquired long QT syndrome: Clinical manifestations, diagnosis, and management", section on 'Patients with acute TdP' and "Catecholaminergic polymorphic ventricular tachycardia" and "Ventricular arrhythmias during acute myocardial infarction", section on 'Polymorphic VT'.)

- **Torsades de pointes** – Polymorphic VT that occurs in the setting of QT prolongation in sinus rhythm is called torsades de pointes (waveform 11).
  - Prompt defibrillation is indicated in patients with hemodynamically unstable torsades de pointes.
  - Intravenous magnesium sulfate (initial dose of 1 to 2 grams IV over 15 minutes, may be followed by an infusion) is first-line therapy, as it is highly effective for both treatment and prevention of recurrence of long QT-related ventricular ectopic beats that trigger torsades de pointes. The benefit is seen even in patients with normal serum magnesium concentrations at baseline.
  - Temporary transvenous overdrive pacing (atrial or ventricular) at about 100 beats per minute is generally reserved for patients who do not respond to intravenous magnesium.
  - In those with congenital long QT syndrome, beta blockers may be used to reduce the frequency of premature ventricular contractions and shorten the QT interval.
  - For patients with torsades de pointes triggered by pauses or bradycardia, isoproterenol (initial dose 0.05 to 0.1 mcg/kg per minute in children and 2 mcg/minute in adults, then titrated to achieve a heart rate of 100 beats per minute) can be used as a temporizing measure to achieve a heart rate of 100 beats per minute prior to pacing.
- **Polymorphic VT due to myocardial ischemia** – For patients with polymorphic VT and a normal baseline QT interval, the most likely cause is myocardial ischemia (waveform 12). Treatments may include:
  - Prompt defibrillation in the hemodynamically unstable patient.
  - Beta-blockers if blood pressure tolerates. Metoprolol 5 mg intravenously every five minutes, to a total of 15 mg, may be given.
  - IV amiodarone may prevent a recurrent episode.
  - Urgent coronary angiography and possible revascularization.
  - Short-term mechanical circulatory support.
  - Magnesium is less likely to be effective for polymorphic VT if the baseline QT interval is normal.
- **Other causes of polymorphic VT** – If the polymorphic VT is due to catecholaminergic polymorphic ventricular tachycardia (CPVT), beta blockers should be used. If it is due to Brugada syndrome, isoproterenol should be initiated (and, if the patient is febrile, reducing the fever). (See "Catecholaminergic polymorphic ventricular tachycardia", section on 'Acute management' and "Brugada syndrome or pattern: Management and approach to screening of relatives".)

Preexcited atrial fibrillation — Patients with preexcited atrial fibrillation (waveform 13) are typically treated with drugs that minimize the risk of rapid conduction of atrial fibrillation or atrial flutter directly to the ventricle or cardioversion, depending on tolerance of the tachyarrhythmia. The approach to patients with an accessory pathway and atrial fibrillation or flutter is discussed separately. (See "Treatment of arrhythmias associated with the Wolff-Parkinson-White syndrome", section on 'Atrial fibrillation with preexcitation (irregular, wide QRS complex)'.)

SOCIETY GUIDELINE LINKS

Links to society and government-sponsored guidelines from selected countries and regions around the world are provided separately. (See "Society guideline links: Atrial fibrillation" and "Society guideline links: Arrhythmias in

adults" and "Society guideline links: Ventricular arrhythmias" and "Society guideline links: Basic and advanced cardiac life support in adults" and "Society guideline links: Supraventricular arrhythmias".)

INFORMATION FOR PATIENTS

UpToDate offers two types of patient education materials, "The Basics" and "Beyond the Basics." The Basics patient education pieces are written in plain language, at the 5th to 6th grade reading level, and they answer the four or five key questions a patient might have about a given condition. These articles are best for patients who want a general overview and who prefer short, easy-to-read materials. Beyond the Basics patient education pieces are longer, more sophisticated, and more detailed. These articles are written at the 10th to 12th grade reading level and are best for patients who want in-depth information and are comfortable with some medical jargon.

Here are the patient education articles that are relevant to this topic. We encourage you to print or e-mail these topics to your patients. (You can also locate patient education articles on a variety of subjects by searching on "patient info" and the keyword(s) of interest.)

- Basics topics (see "Patient education: Tachycardia (The Basics)" and "Patient education: Ventricular tachycardia (The Basics)" and "Patient education: Supraventricular tachycardia (SVT) (The Basics)")

SUMMARY AND RECOMMENDATIONS

- **Initial diagnostic and treatment decisions** – In patients who present with a symptomatic tachyarrhythmia, a 12-lead ECG should be obtained while a brief initial assessment of the patient's overall clinical assessment is performed. If the patient is hemodynamically unstable, it may be preferable to obtain only a rhythm strip prior to urgent cardioversion and not wait for a 12-lead ECG. The information acquired from these initial assessments is crucial for subsequent management of the patient (see 'Initial diagnostic and treatment decisions' above):
  - **Narrow QRS complex tachyarrhythmias** – If the QRS complex is narrow (algorithm 2), the approach to acute management is based on whether the patient is stable or unstable. (See 'Narrow QRS complex tachyarrhythmias' above.)
  - **Wide QRS complex tachyarrhythmias** – If the QRS complex is wide (algorithm 2), the approach to acute management is based on whether the patient is stable or unstable; pulseless patients should be treated according to the adult cardiac life support algorithm (algorithm 5). (See 'Wide QRS complex tachyarrhythmias' above.)

ACKNOWLEDGMENTS

The UpToDate editorial staff acknowledges Philip Podrid, MD, FACC, and Leonard Ganz, MD, FHRS, FACC, who contributed to an earlier version of this topic review.

Use of UpToDate is subject to the Terms of Use.

REFERENCES

1. Wigginton JG, Agarwal S, Bartos JA, et al. Part 9: Adult Advanced Life Support: 2025 American Heart Association Guidelines for Cardiopulmonary Resuscitation and Emergency Cardiovascular Care. Circulation 2025; 152:S538.
2. Link MS. Clinical practice. Evaluation and initial treatment of supraventricular tachycardia. N Engl J Med 2012; 367:1438.

3. Page RL, Joglar JA, Caldwell MA, et al. 2015 ACC/AHA/HRS Guideline for the Management of Adult Patients With Supraventricular Tachycardia: A Report of the American College of Cardiology/American Heart Association Task Force on Clinical Practice Guidelines and the Heart Rhythm Society. J Am Coll Cardiol 2016; 67:e27.
4. Brugada J, Katritsis DG, Arbelo E, et al. 2019 ESC Guidelines for the management of patients with supraventricular tachycardiaThe Task Force for the management of patients with supraventricular tachycardia of the European Society of Cardiology (ESC). Eur Heart J 2020; 41:655.
5. Joglar JA, Chung MK, Armbruster AL, et al. 2023 ACC/AHA/ACCP/HRS Guideline for the Diagnosis and Management of Atrial Fibrillation: A Report of the American College of Cardiology/American Heart Association Joint Committee on Clinical Practice Guidelines. Circulation 2024; 149:e1.
6. Mayuga KA, Fedorowski A, Ricci F, et al. Sinus Tachycardia: a Multidisciplinary Expert Focused Review. Circ Arrhythm Electrophysiol 2022; 15:e007960.
7. Van Gelder IC, Rienstra M, Bunting KV, et al. 2024 ESC Guidelines for the management of atrial fibrillation developed in collaboration with the European Association for Cardio-Thoracic Surgery (EACTS). Eur Heart J 2024; 45:3314.
8. Al-Khatib SM, Stevenson WG, Ackerman MJ, et al. 2017 AHA/ACC/HRS Guideline for Management of Patients With Ventricular Arrhythmias and the Prevention of Sudden Cardiac Death: Executive Summary: A Report of the American College of Cardiology/American Heart Association Task Force on Clinical Practice Guidelines and the Heart Rhythm Society. Circulation 2018; 138:e210.
9. Zeppenfeld K, Tfelt-Hansen J, de Riva M, et al. 2022 ESC Guidelines for the management of patients with ventricular arrhythmias and the prevention of sudden cardiac death. Eur Heart J 2022; 43:3997.

Topic 936 Version 53.0

GRAPHICS

Algorithm 1: **Adult tachycardia with a pulse algorithm 2020 update**

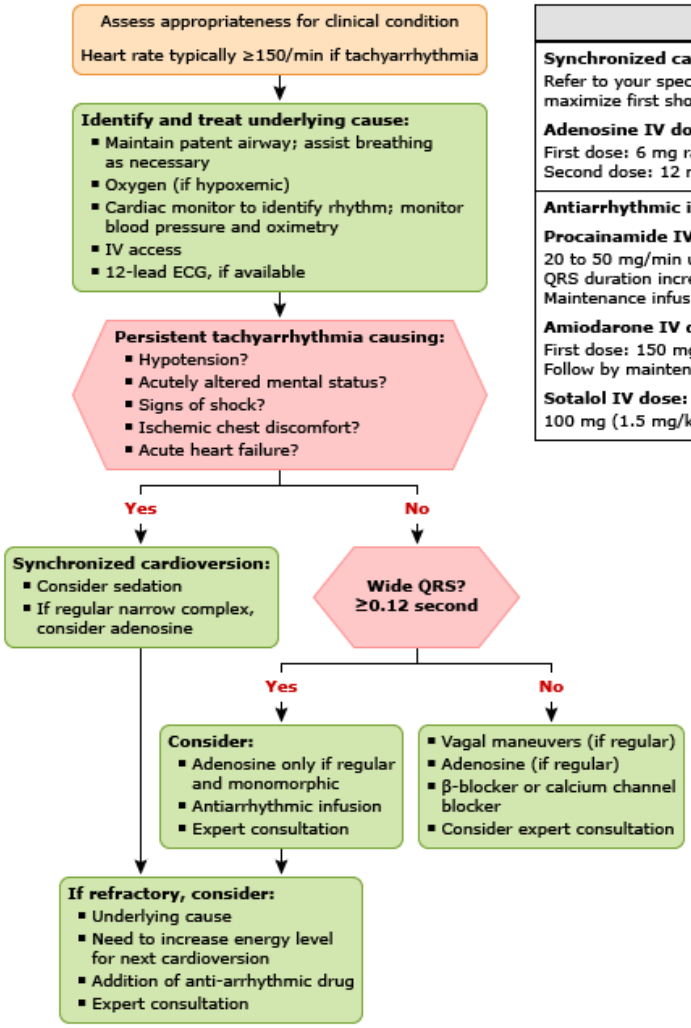

Doses/Details
Synchronized cardioversion: Refer to your specific device's recommended energy level to maximize first shock success.
Adenosine IV dose: First dose: 6 mg rapid IV push; follow with NS flush. Second dose: 12 mg if required.
Antiarrhythmic infusions for stable wide-QRS tachycardia
Procainamide IV dose: 20 to 50 mg/min until arrhythmia suppressed, hypotension ensues, QRS duration increases >50%, or maximum dose 17 mg/kg given. Maintenance infusion: 1 to 4 mg/min. Avoid if prolonged QT or CHF.
Amiodarone IV dose: First dose: 150 mg over 10 minutes. Repeat as needed if VT recurs. Follow by maintenance infusion of 1 mg/min for first 6 hours.
Sotalol IV dose: 100 mg (1.5 mg/kg) over 5 minutes. Avoid if prolonged QT.

Important notice: In October 2025, the American Heart Association released new guidelines on cardiopulmonary resuscitation and emergency cardiovascular care. An updated version of the Adult Tachyarrhythmia With a Pulse Algorithm is now available. This algorithm will be updated within UpToDate in the future.

CHF: congestive heart failure; ECG: electrocardiogram; IV: intravenous; VT: ventricular tachycardia.

Reprinted with permission. ACLS Provider Manual. Copyright © 2020 American Heart Association, Inc.

Graphic 130747 Version 16.0

Algorithm 2: **Algorithm for the initial ECG review and differential diagnosis of tachycardia**

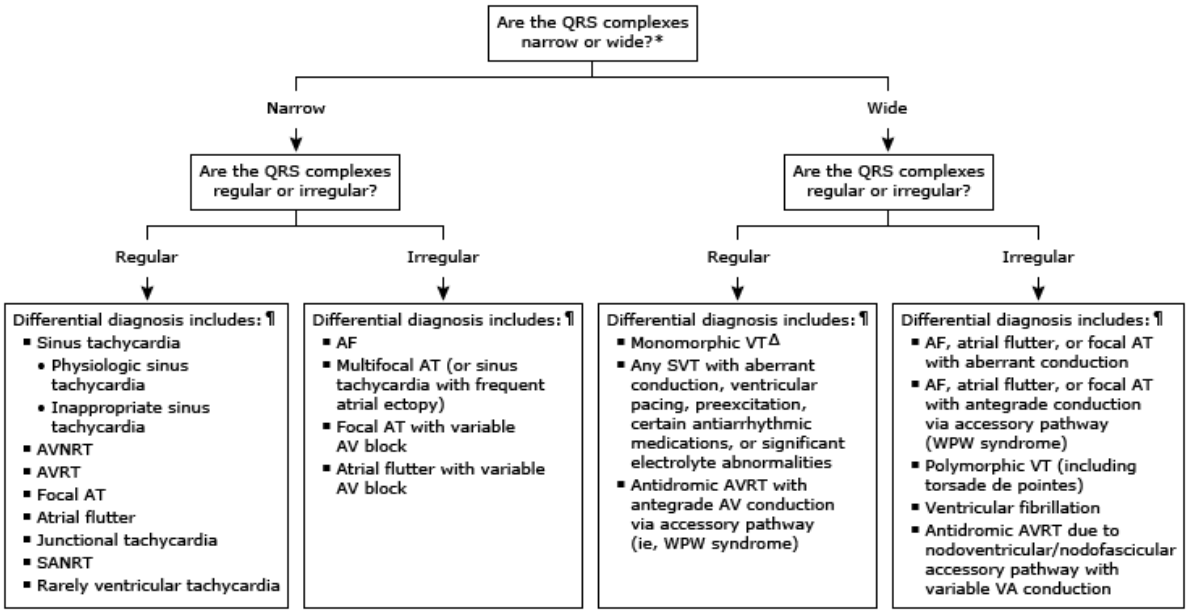

ECG: electrocardiogram; AVNRT: atrioventricular nodal reentrant tachycardia; AVRT: atrioventricular reciprocating (bypass-tract mediated) tachycardia; AT: atrial tachycardia; SANRT: sinoatrial nodal reentrant tachycardia; AF: atrial fibrillation; AV: atrioventricular; VT: ventricular tachycardia; SVT: supraventricular tachycardia; WPW: Wolff-Parkinson-White.
* A narrow QRS complex is <120 milliseconds in duration, whereas a wide QRS complex is ≥120 milliseconds in duration.
¶ Refer to UpToDate topic reviews for additional details on specific ECG findings and management of individual arrhythmias.
Δ Monomorphic VT accounts for 80% of wide QRS complex tachycardias; refer to UpToDate topic on diagnosis of wide QRS complex tachycardias for additional information on discriminating VT from SVT.

Graphic 117571 Version 3.0

Algorithm 3: **Distinguishing among regular narrow QRS complex tachycardias**

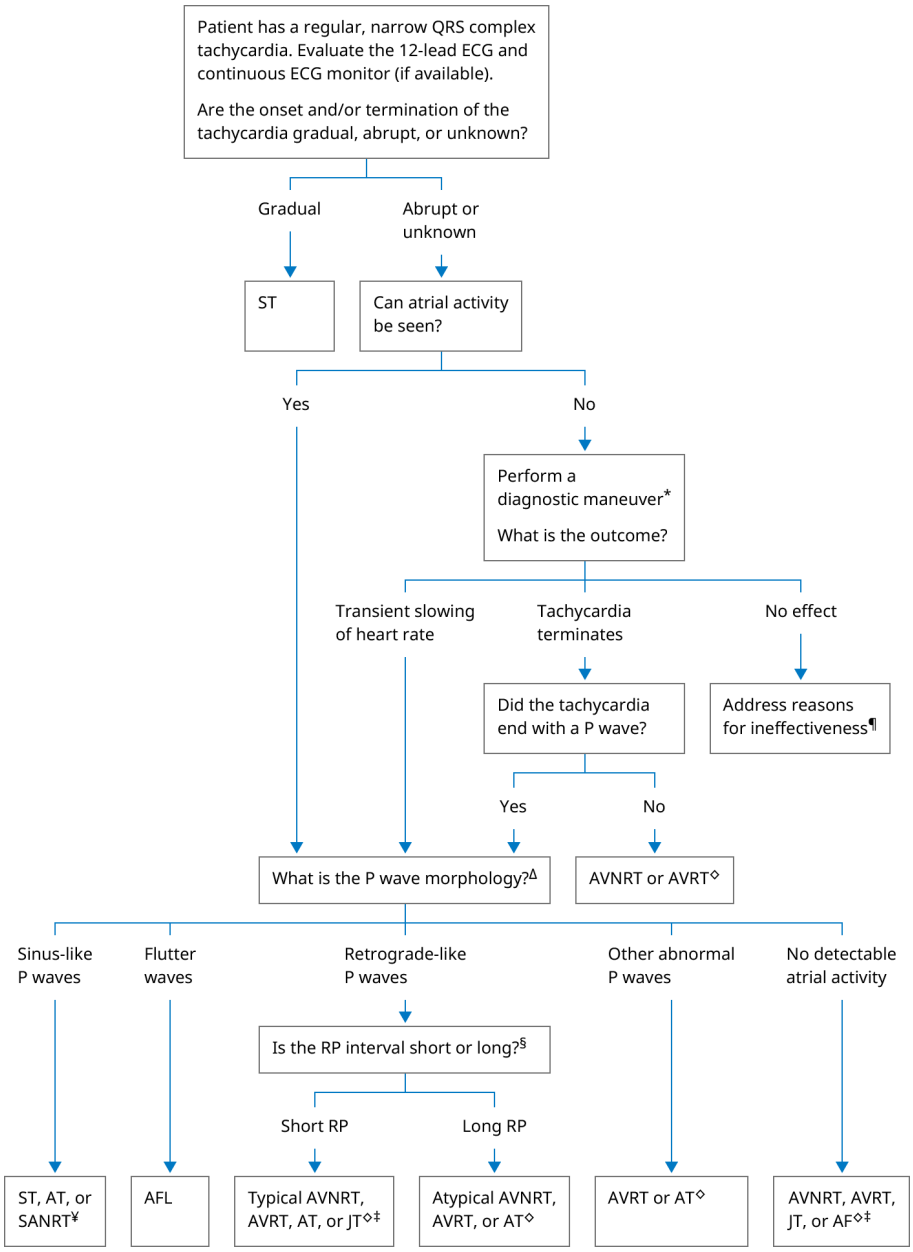

AF: atrial fibrillation; AFL: atrial flutter; AT: atrial tachycardia; AV: atrioventricular; AVNRT: atrioventricular nodal reentrant tachycardia; AVRT: atrioventricular reentrant (reciprocating) tachycardia; ECG: electrocardiogram; IV: intravenous; JT: junctional tachycardia; MAT: multifocal atrial tachycardia; SA: sinoatrial; SANRT: sinoatrial nodal reentrant tachycardia; ST: sinus tachycardia.

* Diagnostic maneuvers (Valsalva maneuver, carotid sinus massage, IV adenosine) cause SA and AV block, making atrial activity more visible. They may also terminate certain tachycardias. We usually start with the Valsalva maneuver if the patient is capable of following instructions. Refer to UpToDate content on narrow QRS complex tachycardia for details.

¶ The Valsalva maneuver or carotid sinus massage may have been performed incorrectly. Adenosine may have been administered too slowly or a higher dose may be needed. The diagnostic maneuver should be repeated with correct technique or a different one should be chosen.

Δ Refer to UpToDate content on narrow QRS complex tachycardias for a discussion of P wave morphologies.

◇ If there is a delta wave on the sinus ECG, the tachycardia was AVRT. Lack of a delta wave does not rule out AVRT because some accessory pathways do not exhibit antegrade conduction.

§ The RP interval is the time from the onset of the QRS to the onset of the subsequent P wave. In a short RP tachycardia, the RP interval is less than half of the RR interval. Refer to UpToDate content on narrow QRS complex tachycardias for details.

¥ In general, ST is most likely. However, ST is unlikely if any of the following are true: the rhythm terminated with diagnostic maneuvers, the onset or termination of the tachycardia was abrupt, the atrial rate is >200 bpm, or there is evidence of AV block.

‡ If the tachycardia terminated with diagnostic maneuvers, it was probably AVNRT or AVRT.

Graphic 149312 Version 1.0

Waveform 1: **Sinus tachycardia**

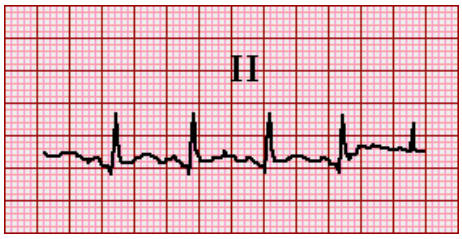

Sinus tachycardia is defined as a sinus rhythm with a rate of greater than 100 beats per minute and less than approximately 160 to 180 beats per minute. In this tracing, the rate is about 130 beats per minute.

Graphic 56631 Version 2.0

Sinus rhythm

The normal P wave in sinus rhythm is slightly notched since activation of the right atrium precedes that of the left atrium. The P wave is upright in a positive direction in leads I and II. A P wave with a uniform morphology precedes each QRS complex. The rate is between 60 and 100 beats per minute and the cycle length is uniform between sequential P waves and QRS complexes. In addition, the P wave morphology and PR intervals are identical from beat to beat.

Graphic 69872 Version 2.0

Waveform 2: **Sinus tachycardia on 12-lead electrocardiogram**

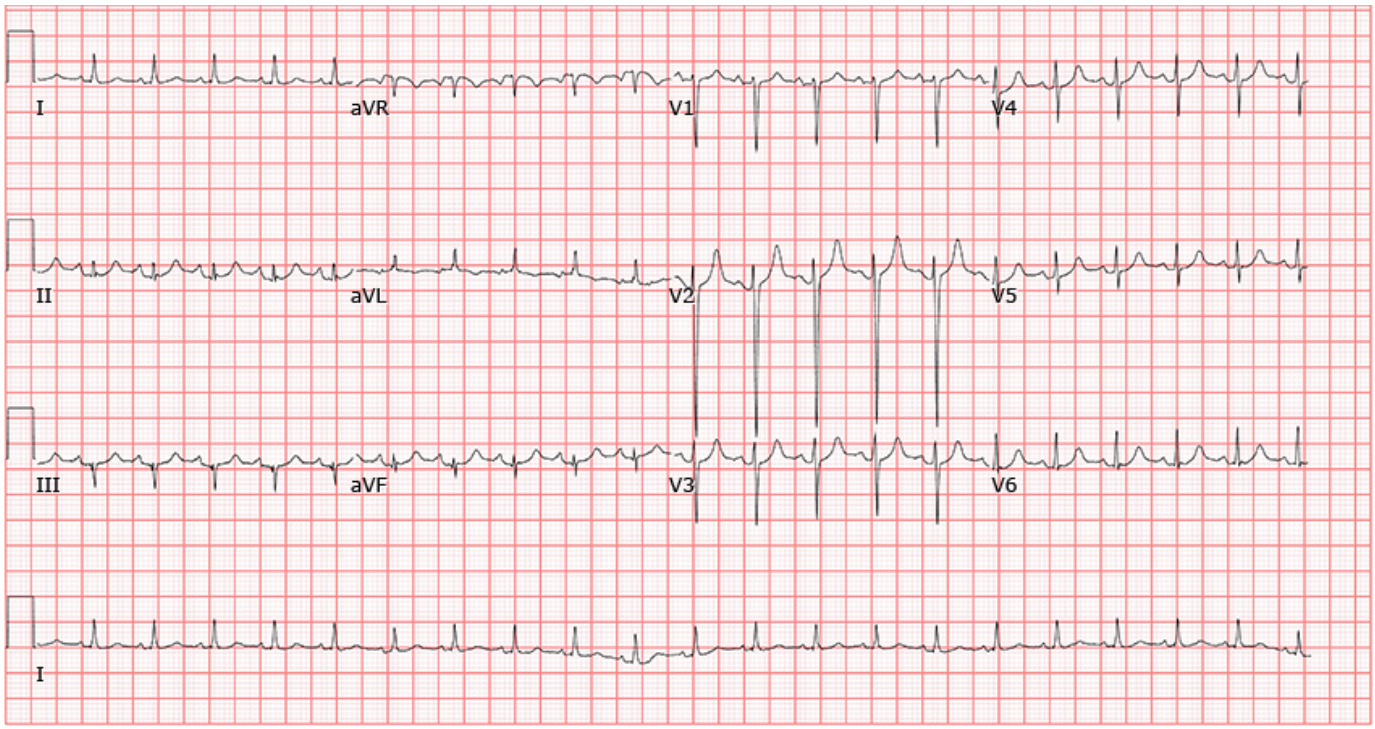

12-lead electrocardiogram showing sinus tachycardia at 126 beats per minute.

Graphic 150763 Version 1.0

Figure 1: **Atypical atrioventricular nodal reentrant tachycardia**

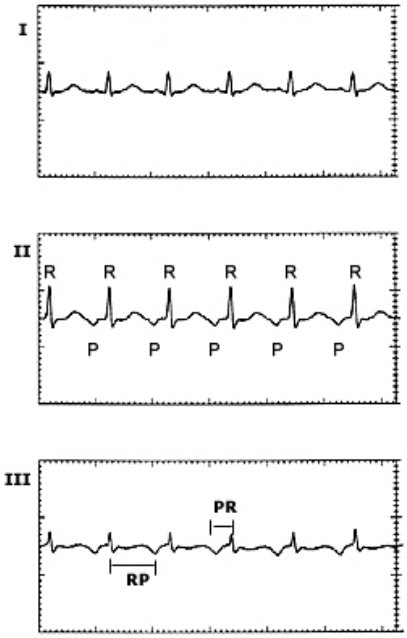

Shown are three simultaneous ECG leads (I, II, and III) during an uncommon or atypical form of an atrioventricular nodal reentrant tachycardia (AVNRT) in which antegrade conduction to the ventricle is via the fast pathway and retrograde atrial activation is by the slow pathway. As a result of delayed atrial activation, there is a long RP and short PR interval and a negative P wave in the inferior leads II and III.

Graphic 66828 Version 2.0

Algorithm 4: **Approach to adenosine dosing in stable adults with suspected supraventricular tachyarrhythmia**

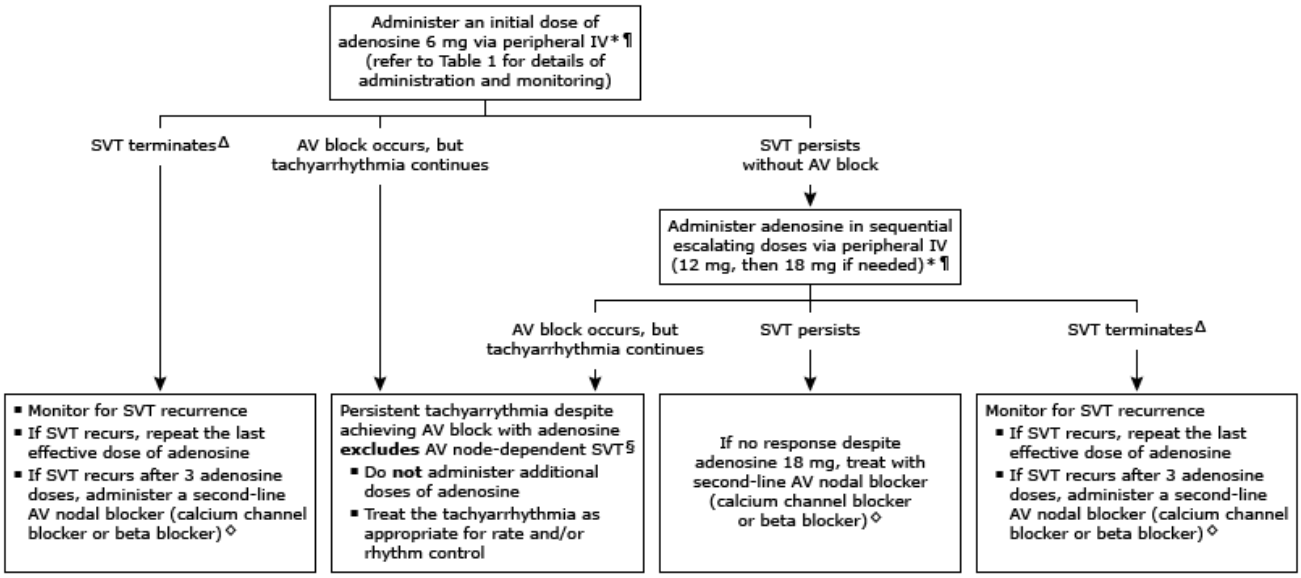

Table 1

Best practices for adenosine administration:

- The patient should be supine during adenosine administration and subsequent monitoring.
- Monitor blood pressure and record a 12-lead ECG during and for 1 to 2 minutes after administration to assess the response to adenosine. If a 12-lead ECG is impractical, record telemetry.
- Administer adenosine in the most proximal available peripheral IV site (eg, antecubutal vein); administration via a hand IV site is generally avoided. If central venous administration of adenosine is performed, lower doses are used than for peripheral administration.¶
- Administer adenosine via a 3-way stopcock, with 1 port leading to the patient, 1 port for the adenosine dose, and 1 port for normal saline flush (10 to 20 mL). Both the adenosine and normal saline syringes should be attached before adenosine is given.
- The IV adenosine dose is pushed over 1 to 2 seconds, immediately followed by turning the stopcock for normal saline flush over 1 to 2 seconds.

This figure summarizes the initial dosing, administration, and need for repeat dosing of adenosine in a hemodynamically stable adult with suspected AV node-dependent SVT. Adenosine can be used as a diagnostic aid to identify the underlying rhythm or as a therapy to terminate SVTs that rely on AV node conduction. AV node-dependent SVTs include AV nodal reentrant tachycardia (AVNRT) and AV reentrant (or reciprocating) tachycardia (AVRT). The management of suspected AV node-dependent SVT in hemodynamically stable adults commonly starts with a trial of 1 or more vagal maneuvers prior to proceeding to adenosine therapy. If the patient has hemodynamically unstable SVT, cardioversion is indicated. Refer to UpToDate content for details on management of SVTs.

AV: atrioventricular; SVT: supraventricular tachycardia; IV: intravenous; ACC: American College of Cardiology; AHA: American Heart Association; HRS: Heart Rhythm Society; ECG: electrocardiogram.

* Lower adenosine doses are indicated in certain clinical settings. If central venous administration is performed, the initial adenosine dose is 3 mg; if needed (SVT persists and there is no AV block), the dose may be increased to 6 mg and then 9 mg for subsequent doses. For heart transplant recipients, the initial adenosine dose is 1 mg; if needed (SVT persists and there is no AV block), the dose may be increased to 2 mg and then 3 mg for subsequent doses.

¶ An 18 mg dose is more likely to be required to produce AV block in patients with a body weight >70 kg, particularly in those weighing >110 kg.[1] When a third dose is indicated, an alternative approach is to administer 12 mg (instead of 18 mg) as described in the 2015 ACC/AHA/HRS Guideline for the Management of Adult Patients with Supraventricular Tachycardia.[2]

∆ SVT termination in response to adenosine includes SVT termination closely followed by SVT recurrence.

◇ Refer to UpToDate content on treatment of SVT for dosing of second-line AV nodal blockers. If the SVT persists despite second-line AV nodal blocker therapy, electrical cardioversion is performed, as discussed in UpToDate content on treatment of SVT.

§ SVTs that are **not** AV node dependent include atrial flutter, atrial fibrillation, and atrial tachycardia. When AV nodal block is induced by adenosine, the ECG may reveal atrial activity diagnostic of these rhythms.

References:

1. *Prabhu S, Mackin V, McLellan AJA, et al. Determining the optimal dose of adenosine for unmasking dormant pulmonary vein conduction following atrial fibrillation ablation: Electrophysiological and hemodynamic assessment. DORMANT-AF study. J Cardiovasc Electrophysiol 2017; 28:13.*
2. *Page RL, Joglar JA, Caldwell MA, et al. 2015 ACC/AHA/HRS guideline for the management of adult patients with supraventricular tachycardia: A report of the American College of Cardiology/American Heart Association Task Force on Clinical Practice Guidelines and the Heart Rhythm Society. Circulation 2016; 133:e506.*

Graphic 141417 Version 3.0

Waveform 3: **12-lead electrocardiogram (ECG) showing orthodromic atrioventricular reentrant tachycardia (AVRT) in a patient with an accessory AV pathway**

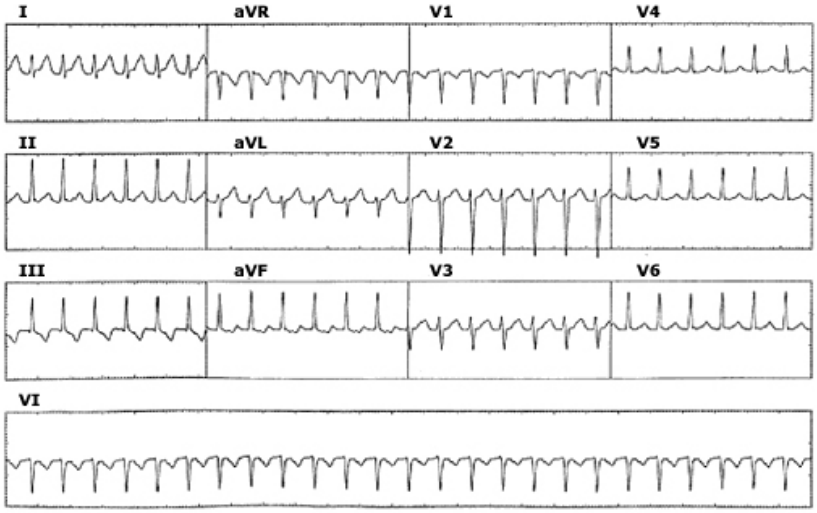

The 12-lead ECG from a patient with Wolff-Parkinson-White shows a regular tachycardia. However, in contrast to the QRS pattern during sinus rhythm, the QRS complexes are narrow, without evidence of a delta wave or pre-excitation; this is due to the fact that antegrade ventricular activation occurs via the normal atrioventricular node-His Purkinje pathway, while retrograde atrial activation is via the accessory pathway. Therefore, this is called an orthodromic atrioventricular reentrant tachycardia (OAVRT).

Courtesy of Martin Burke, DO.

Graphic 68804 Version 5.0

ECG in Wolff-Parkinson-White

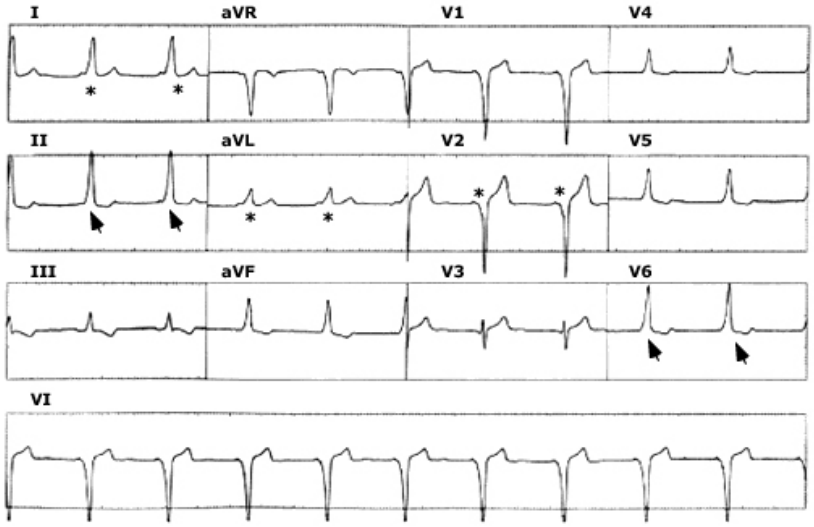

The 12-lead ECG shows the typical features of Wolff-Parkinson-White; the PR interval is short (*) and the QRS duration prolonged as a result of a delta wave (arrow), indicating ventricular preexcitation.

Courtesy of Martin Burke, DO.

Graphic 67181 Version 3.0

Waveform 4: **Electrocardiogram showing an ectopic atrial tachycardia originating from the tricuspid annulus**

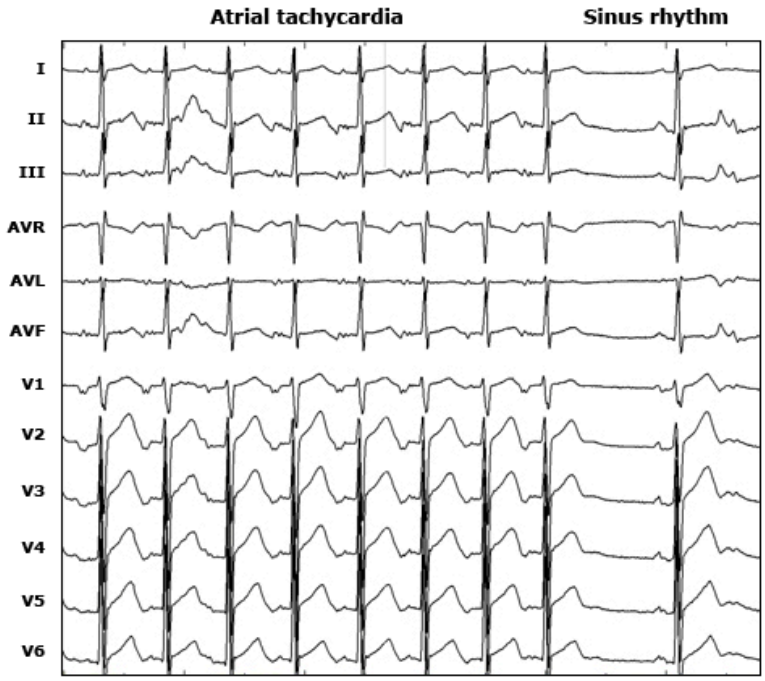

Electrocardiographic tracing showing a narrow complex tachycardia with uniform P waves consistent with an ectopic atrial tachycardia originating from the tricuspid annulus. Prior to the final QRS complex, there is spontaneous return to normal sinus rhythm with P wave of a different morphology.

Courtesy of Peter Kistler, MBBS, FRACP, PhD.

Graphic 74611 Version 10.0

Waveform 5: **Typical atrial flutter**

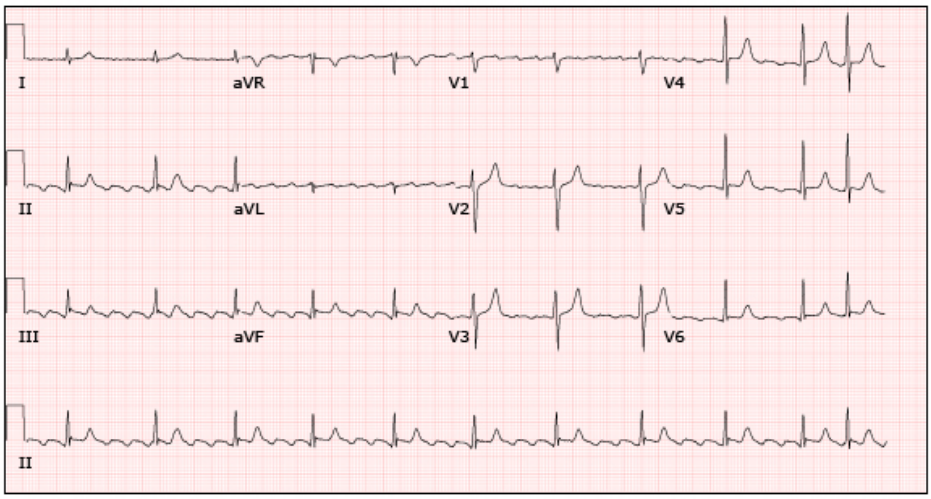

Electrocardiogram in type I counterclockwise typical atrial flutter. The biphasic flutter (F) waves are prominently negative (lead II) in counterclockwise typical flutter. The patient is on a beta-blocker which explains the predominant 4:1 conduction pattern.

Graphic 74395 Version 4.0

Waveform 6: **Atrial fibrillation with a slow, moderate, and rapid ventricular response**

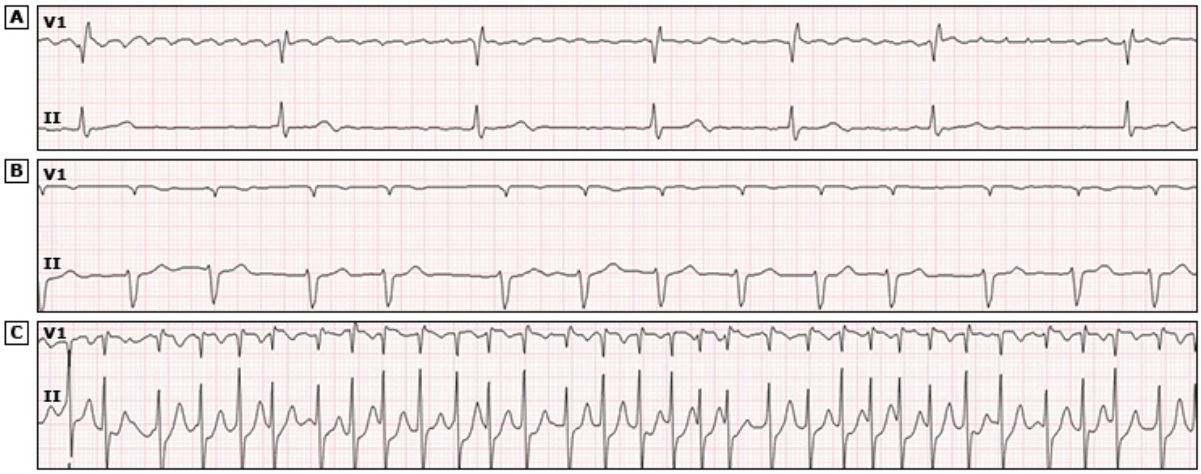

Atrial fibrillation with a slow (A), moderate (B), and rapid (C) ventricular response. Lead V1 and lead II rhythm strips show irregularly irregular rhythms without discrete P waves and with fibrillatory atrial activity.

Graphic 132159 Version 1.0

Waveform 7: **Multifocal atrial tachycardia on 12-lead electrocardiogram**

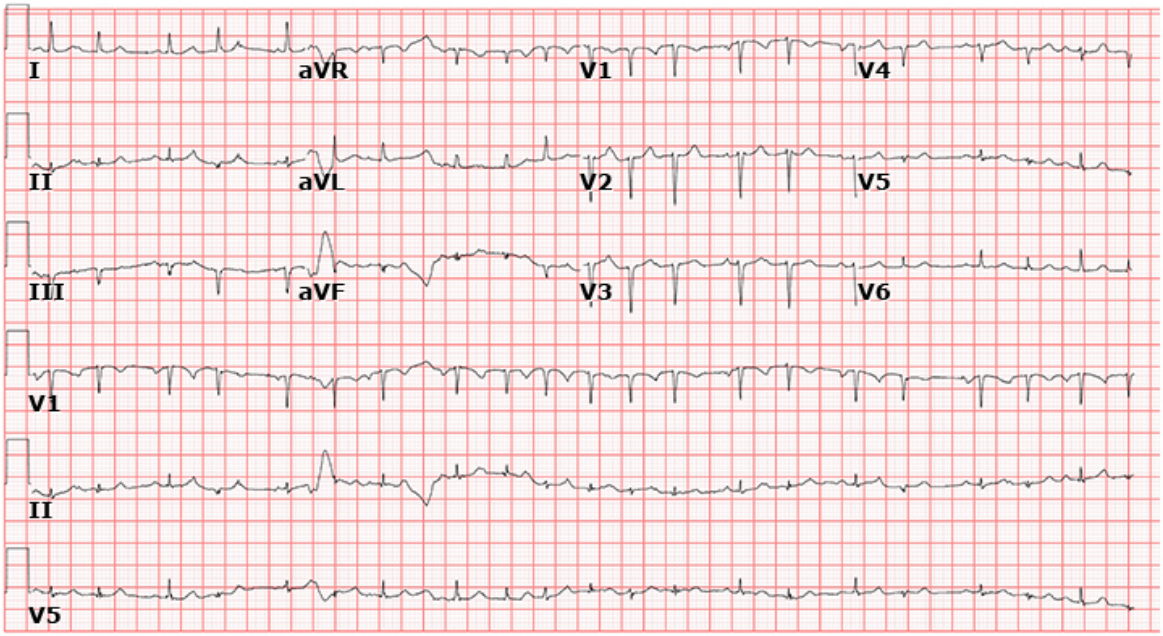

12-lead electrocardiogram showing multifocal atrial tachycardia. There are at least three P wave morphologies with varying PR intervals.

Graphic 150759 Version 1.0

Waveform 8: **Supraventricular tachycardia with ventricular pacing**

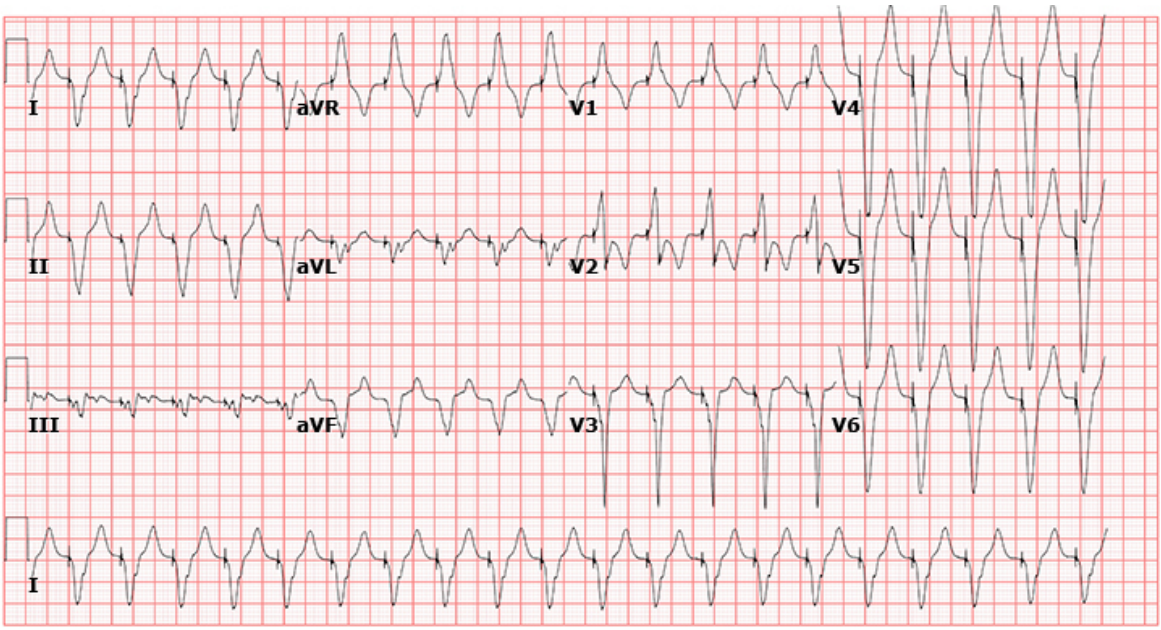

12-lead electrocardiogram showing supraventricular tachycardia with ventricular pacing. The underlying rhythm is likely atrial tachycardia. P waves are best seen in lead III.

Graphic 150758 Version 1.0

Algorithm 5: **Adult cardiac arrest algorithm**

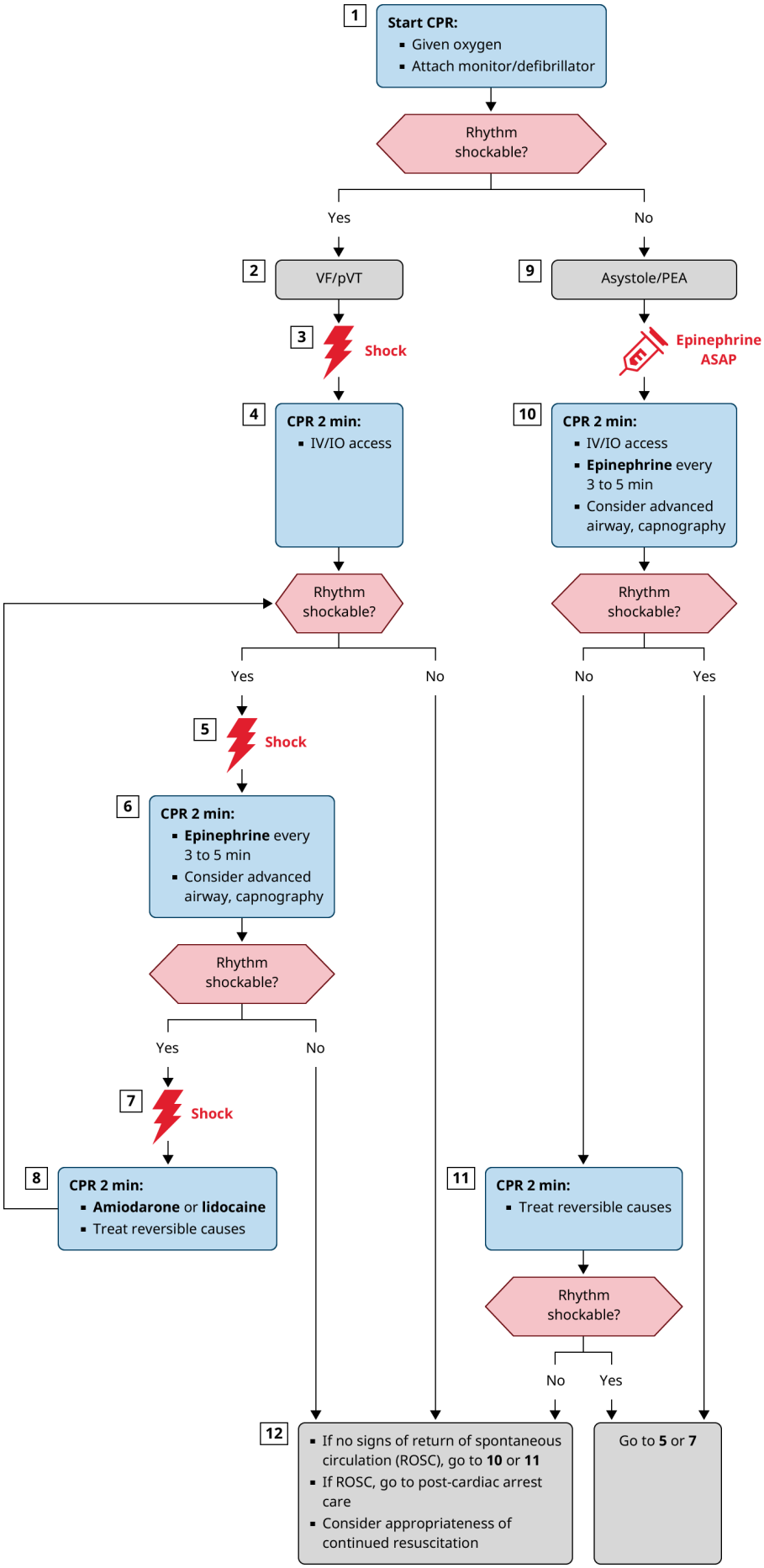

CPR quality

- Push hard (at least 2 inches [5 cm]) and fast (100 to 120/min) and allow complete chest recoil.
- Minimize interruptions in compressions.
- Avoid excessive ventilation.
- Change compressor every 2 minutes, or sooner if fatigued.
- If no advanced airway, 30:2 compression-ventilation ratio.
- Quantitative waveform capnography
  - If $PETCO_2$ is low or decreasing, reassess CPR quality.

Shock energy for defibrillation

- **Biphasic:** Manufacturer recommendation (eg, initial dose of 120 to 200 J); if unknown, use maximum available. Second and subsequent doses should be equivalent, and higher doses may be considered.
- **Monophasic:** 360 J.

Drug therapy

- **Epinephrine IV/IO dose:**
  1 mg every 3 to 5 minutes.
- **Amiodarone IV/IO dose:**
  First dose: 300 mg bolus.
  Second dose: 150 mg.

  or
- **Lidocaine IV/IO dose:**
  First dose: 1 to 1.5 mg/kg.
  Second dose: 0.5 to 0.75 mg/kg.

Advanced airway

- Endotracheal intubation or supraglottic advanced airway.
- Waveform capnography or capnometry to confirm and monitor ET tube placement.
- Once advanced airway in place, give 1 breath every 6 seconds (10 breaths/min) with continuous chest compressions.

Return of spontaneous circulation (ROSC)

- Pulse and blood pressure.
- Abrupt sustained increase in $PETCO_2$ (typically ≥40 mmHg).
- Spontaneous arterial pressure waves with intra-arterial monitoring.

Reversible causes

- **H**ypovolemia
- **H**ypoxia
- **H**ydrogen ion (acidosis)
- **H**ypo-/hyperkalemia
- **H**ypothermia
- **T**ension pneumothorax
- **T**amponade, cardiac
- **T**oxins
- **T**hrombosis, pulmonary
- **T**hrombosis, coronary

Important notice: In October 2025, the American Heart Association released new guidelines on cardiopulmonary resuscitation and emergency cardiovascular care. An updated version of the Adult Cardiac Arrest Algorithm is now available.

This algorithm will be updated within UpToDate in the future.

ET: endotracheal; IO: intraosseous; IV: intravenous; J: joules; PEA: pulseless electrical activity; $PETCO_2$: peak end-tidal carbon dioxide; pVT: pulseless ventricular tachycardia; ROSC: return of spontaneous circulation; VF: ventricular fibrillation.

Reprinted with permission. Highlights of the 2020 American Heart Association Guidelines for CPR and ECC. Copyright © 2020 American Heart Association, Inc.

Graphic 129983 Version 14.0

Waveform 9: **12-lead ECG sustained monomorphic VT**

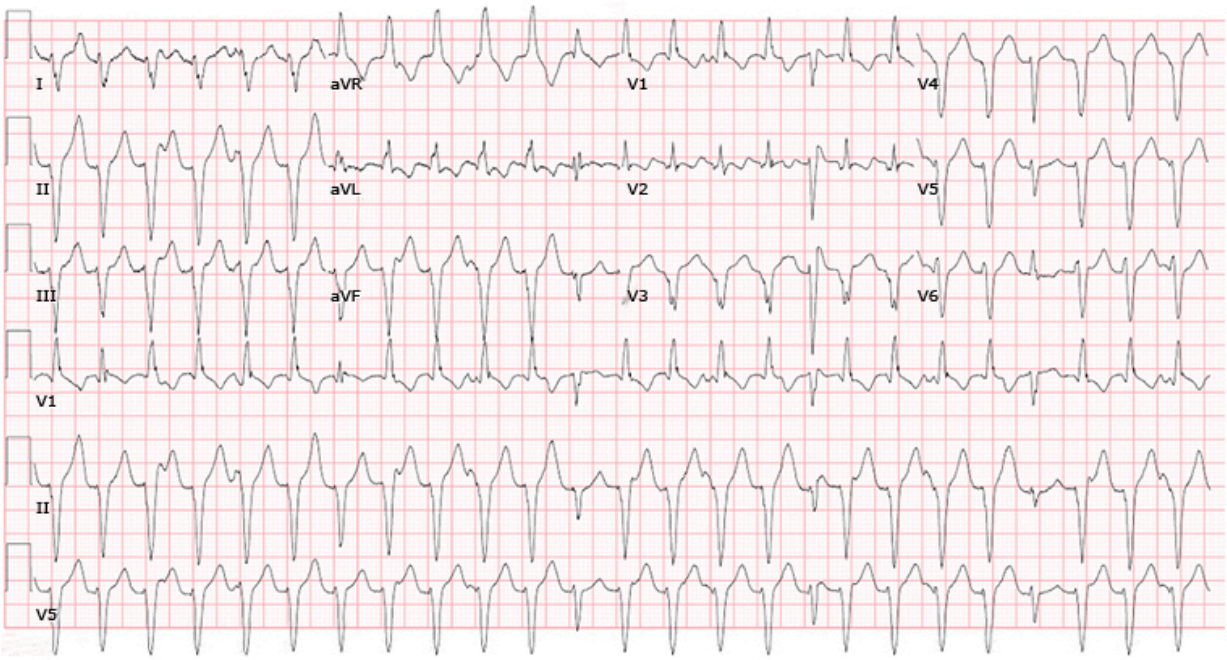

The electrocardiogram (ECG) hallmark for the diagnosis of sustained monomorphic ventricular tachycardia (SMVT) is a wide complex tachycardia with the obvious presence of atrioventricular (AV) dissociation. AV dissociation is suggested by the presence of fusion complexes (which reflect a supraventricular impulse coming from above the AV node fusing with an impulse generated in the ventricle) or captured complexes (which reflect an impulse coming from above the AV node that depolarizes the ventricles when they are no longer refractory but before the next ventricle-generated complex). Beats 12, 17, and 22 on this ECG likely represent capture beats.

Graphic 111254 Version 1.0

Waveform 10: **Sustained monomorphic ventricular tachycardia with atrioventricular dissociation**



Sustained monomorphic ventricular tachycardia on 12-lead electrocardiogram. There is evidence of atrioventricular dissociation (eg, P waves unrelated to QRS complexes) that is best appreciated in leads V1 and V2.

Graphic 150778 Version 1.0

Algorithm 6: **Acute management of sustained monomorphic ventricular tachycardia in patients with a pulse**

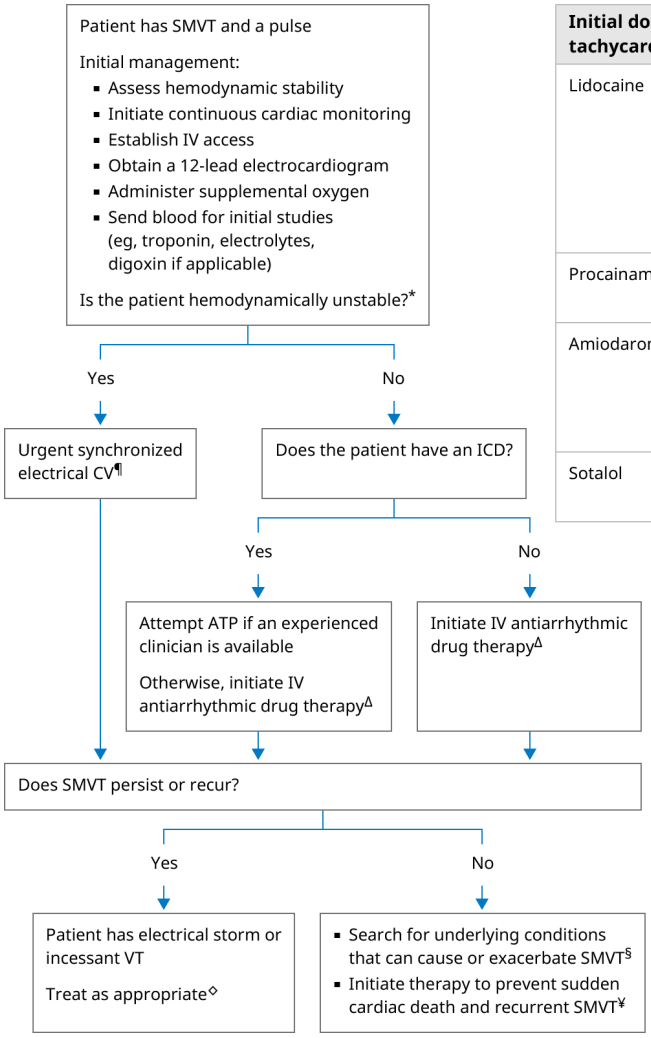

Initial dosing of IV antiarrhythmic drugs for ventricular tachycardia	
Lidocaine	1 to 1.5 mg/kg (typically 50 to 100 mg) IV bolus administered at a rate of 25 to 50 mg/minute. May give additional doses of 0.5 to 0.75 mg/kg every 5 to 10 minutes as needed. Maximum cumulative dose 3 mg/kg or 300 mg within 1 hour.
Procainamide‡	20 to 50 mg/minute until arrhythmia terminates or a total dose of 15 to 17 mg/kg (1500 mg) is reached.
Amiodarone	150 mg IV bolus over 10 minutes, then 1 mg/minute for 6 hours, then 0.5 mg/minute for 18 hours. Repeated 150 mg boluses can be given if needed, up to 2.2 grams in the first 24 hours.
Sotalol	1.5 mg/kg (or 100 mg) IV bolus administered over 5 minutes.

ATP: antitachycardia pacing; CV: cardioversion; ICD: implantable cardioverter-defibrillator; IV: intravenous; MI: myocardial infarction; SMVT: sustained monomorphic ventricular tachycardia; VT: ventricular tachycardia.

* Hemodynamically unstable patients have 1 or more of the following: hypotension, signs of shock, altered mental status, chest pain, or acute heart failure.

¶ Synchronized electrical CV should be performed using a 200 joule (biphasic) or 360 joule (monophasic) shock. Subsequent shocks should be at the maximum energy of the device.

Δ Lidocaine is preferred in the setting of acute MI. In other patients, any drug may be used. Refer to UpToDate content on SMVT treatment for guidance on choosing a drug. Refer to inset for dosing recommendations.

◇ Refer to UpToDate content on the treatment of electrical storm and incessant VT.

§ Conditions that can cause or exacerbate SMVT include myocardial ischemia, electrolyte disturbance (eg, hypokalemia, hypomagnesemia), and drug-related proarrhythmia.

¥ ICDs are recommended for most patients to prevent sudden cardiac death. Therapies to prevent recurrent SMVT include radiofrequency ablation and oral antiarrhythmic drugs. Refer to UpToDate content about prevention of recurrent SMVT in patients with structural heart disease.

‡ Procainamide dose reductions are required for kidney and liver function impairment. Refer to separate procainamide infusion algorithm and the drug monograph in UpToDate for more detail on dosing and monitoring.

Graphic 149328 Version 2.0

Waveform 11: **Single lead electrocardiogram (ECG) showing polymorphic ventricular tachycardia (VT)**

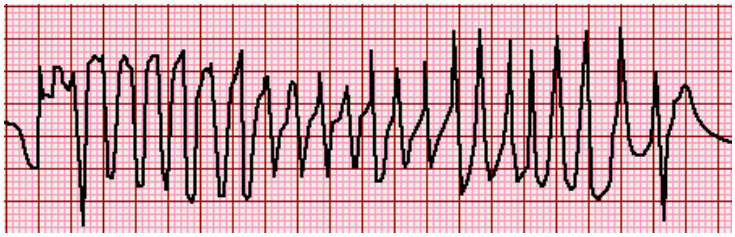

This is an atypical, rapid, and bizarre form of ventricular tachycardia that is characterized by a continuously changing axis of polymorphic QRS morphologies.

Graphic 53891 Version 5.0

Waveform 12: **ECG_1 showing polymorphic ventricular tachycardia in ischemia**

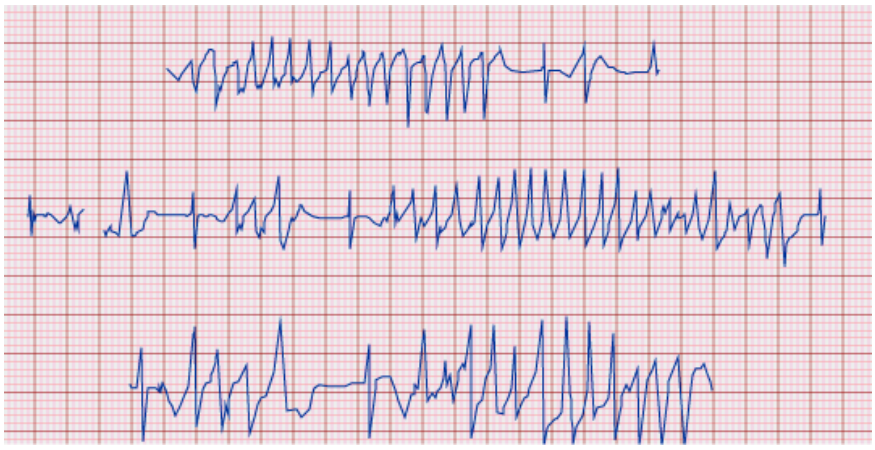

Continuous rhythm strip revealing several episodes of nonsustained ventricular tachycardia (VT) occurring during an acute ischemic event. The QRS complexes are variable in morphology and RR intervals; thus, the VT is polymorphic. The QT interval is normal. This form of VT should be distinguished from torsade de pointes in which polymorphic VT is associated with QT interval prolongation.

Graphic 54538 Version 3.0

Waveform 13: **ECG pre-excited atrial fibrillation**



12-lead ECG showing atrial fibrillation in a patient with antegrade conduction through both the AV node and an accessory pathway. The occasional narrow QRS complexes reflect conduction through the AV node, while the wide QRS complexes, with instantaneous rates close to 300 beats per minute, are due to antegrade conduction via an accessory pathway (probably postero-septal based on the QRS morphology).

AV: atrioventricular; ECG: electrocardiogram.

Reproduced with permission from: Nathanson LA, McClennen S, Safran C, Goldberger AL. ECG Wave-Maven: Self-Assessment Program for Students and Clinicians. Copyright © Beth Israel Deaconess Medical Center. https://ecg.bidmc.harvard.edu (Accessed on April 19, 2018).

Graphic 117553 Version 2.0

Contributor Disclosures

Jordan M Prutkin, MD, MHA, MHS No relevant financial relationship(s) with ineligible companies to disclose. **James Hoekstra, MD** No relevant financial relationship(s) with ineligible companies to disclose. **Hugh Calkins, MD** Grant/Research/Clinical Trial Support: Biosense [Atrial fibrillation]; Boston Scientific [Atrial fibrillation]; Kardium [Atrial fibrillation]. Consultant/Advisory Boards: Abbott [Atrial fibrillation]; Atricure [Atrial fibrillation]; Biosense Webster [Catheter ablation]; Boston Scientific [ARVC and atrial fibrillation]; Medtronic [Atrial fibrillation]. Other Financial Interest: Boston Scientific [Lecture honoraria]; Medtronic [Lecture honoraria]. All of the relevant financial relationships listed have been mitigated. **Brian Olshansky, MD** No relevant financial relationship(s) with ineligible companies to disclose. **Naomi F Botkin, MD** No relevant financial relationship(s) with ineligible companies to disclose.

Contributor disclosures are reviewed for conflicts of interest by the editorial group. When found, these are addressed by vetting through a multi-level review process, and through requirements for references to be provided to support the content. Appropriately referenced content is required of all authors and must conform to UpToDate standards of evidence.

Conflict of interest policy

→